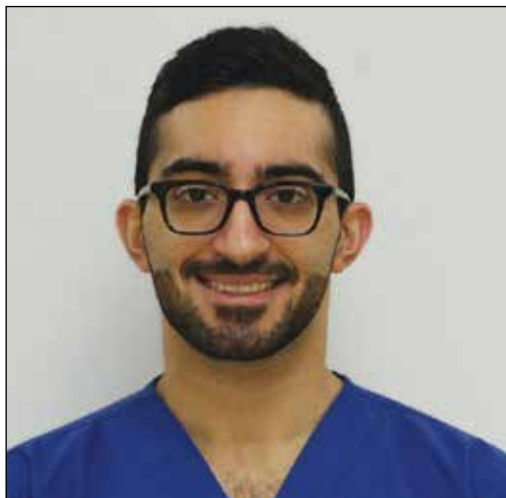



Test 223
dentalCEtoday.com



Ahmad Soolari, DMD, MS, is a Diplomate and examiner of the American Board of Periodontology. He has a certificate in periodontics from Eastman Dental and an MS degree from the University of Rochester in New York. He is a former clinical associate professor at the University of Maryland School of Dentistry (UMSOD) in Baltimore. Dr. Soolari operates specialty practices in Maryland in Silver Spring, Gaithersburg, and Potomac. He can be reached via email at drsoolari@hotmail.com.



Amin Soolari, BS, CDRT, is a second-year dental student at UMSOD, and he earned a bachelor's degree in biological science from the University of Maryland. He has been a dental assistant for 6 years and has experience in orthodontics and periodontics and assisting in general treatment and oral surgery. He started his career in a periodontal office, where he became a Certified Dental Radiation Technologist (CDRT) in 2012. He can be reached via email at amin.soolari@gmail.com.

Disclosure: The authors report no disclosures.

Treatment Planning in Immunocompromised Patients: Case Report

This article presents a case involving a patient with numerous oral and systemic health problems, including human immunodeficiency virus (HIV), hepatitis B and C, arthritis, chronic kidney disease, and smoking. The planning and treatment approach demonstrates that such patients can be successfully treated in the dental setting.

An estimated 1.1 million individuals in the United States are living with human immunodeficiency virus (HIV).¹ The virus is transmitted through blood and genital fluids and targets the host immune system, specifically CD4 cells.² HIV has 3 stages: the acute infection phase, the clinical latency phase, and the acquired immunodeficiency syndrome (AIDS) phase.³ The acute phase is seen 2 to 4 weeks after infection and presents as flu-like symptoms. The latency stage is characterized by an increase in viral load counts and a decrease in CD4 cell count, leading to the final stage of AIDS, in which the patient is susceptible to opportunistic and other infections.^{3,4}

The viral load measurement is a good predictor of disease progression, especially in patients who abuse drugs,⁵ as drug abuse is often associated with serious oral health problems.⁶ Drug abuse is a multi-systemic disorder that requires a multi-professional approach, and oral healthcare can have a positive and rehabilitative effect on patients.⁶ Along with medical issues, patients who abuse drugs also suffer from behavioral disorders, psychological issues, and trouble managing pain and controlling cross-infections, all of which should be considered when planning treatment.⁷

This article presents a case involving a patient with numerous oral health problems, including periodontal disease, unreplaced missing teeth, tooth migration, broken-down teeth, caries, a periodontal abscess, gingival recessions, abfraction, endodontic concerns, root tips, collapsed occlusion, and aesthetic problems. Reviewing the patient's medical history revealed that the patient was HIV and hepatitis B and C positive, had arthritis and chronic kidney disease, and was a smoker. Communications with an infectious disease physician revealed that the patient's CD4 count was 584 (the normal range is 500 to 1,500) and his medical condition was controlled with medication and, therefore, stable.

CASE REPORT

The patient was a 60-year-old African-American male who presented to the authors' office with a chief complaint of not being able to "smile, chew, or speak properly." Clinical and radiographic evaluation disclosed poor oral health involving severe periodontal, endodontic, and prosthodontic complications, including posterior bite collapse (Figures 1 and 2). The patient's medical history was significant, as he was a smoker and a hepatitis B and C carrier with a compromised immune system and a history of drug abuse. The patient was suffering from dental neglect that negatively affected his oral and overall health.

Optimal care for such a patient must include personalized education, prevention, and treatment planning to improve oral health and minimize systemic complications. This is somewhat different from the classic All-on-4 approach. The treatment plan was discussed and coordinated with the patient's infection control physician to ensure that the oral healthcare would positively affect the patient's systemic and psychological well-being. Informed consent was obtained in writing from the

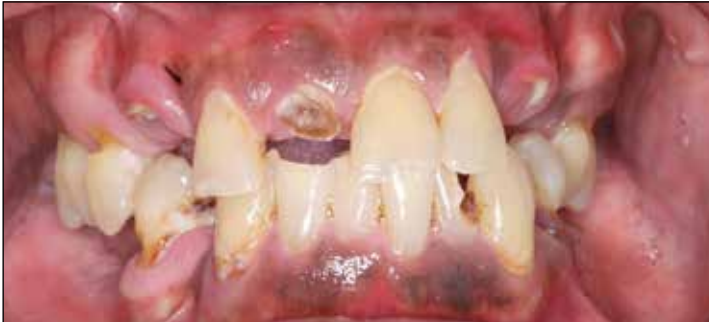

Figure 1. The frontal view, disclosing the severity of the patient's compromised oral health.

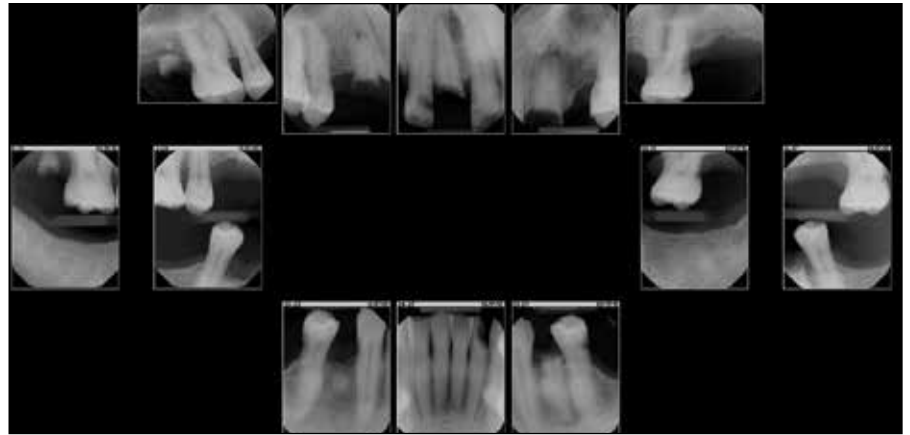


Figure 2. The full-mouth series of radiographs disclosed caries, endodontic lesions, unreplaced missing teeth, and supra-eruption.

patient, extraoral 3-D images were taken, and a diagnostic model was prepared for a temporary prosthesis prior to removing teeth (Figure 3). The patient was pre-medicated orally with the anti-infective agent amoxicillin (500 mg 3 times daily), the analgesic ibuprofen (600 mg 3 times daily, as needed), and the anti-swelling medications methylprednisolone (Medrol Dosepack, taken as directed) and chlorhexidine rinse (Aclean, chlorhexidine gluconate, 16 oz, 0.12% oral rinse [Henry Schein] twice daily).

Crestal incisions were made throughout to access bone and tooth roots, except in the area of broken-down teeth with deep intrabony defects, where vertical incisions were made instead. A 15C surgery blade (carbon steel [Benco Dental]) was used for an intrasulcular incision and

Special strategies are required for patients with oral and systemic conditions....

the placement of 2 vertical incisions. The flap elevation extended beyond the mucogingival junction for the area and had deep bony defects in the areas of teeth Nos. 6, 8, and 11. All teeth in the maxilla and mandible were removed, with the exception of teeth Nos. 22 and 24 through 27. The bony defect was debrided to facilitate ridge augmentation prior to coronal advancement of the flap. Next, bone grafting was performed with freeze-dried bone allograft from Maxxeus Dental (cortical bone, DNo25), and a non-resorbable, titanium-reinforced Cytoplast Membrane (Osteogenics Biomedical) was trimmed and customized to promote bone regeneration. Flaps were closed using a 4.0 white monofilament non-absorbable suture (Cytoplast PTFE [Osteogenics Biomedical]). This treatment assisted in maintaining the height and width of the ridge, in addition to rebuilding the lost jawbone. A provisionalized denture was delivered for the maxilla and mandible.

Eight weeks later, a CBCT image was taken to evaluate the quality and quantity of bone prior to implant insertion. This was followed by removal of the non-resorbable membrane, insertion of 4 implants (Implant Direct), and denture adjustment (Figure 4). Implants were placed in strategic positions to provide symmetrical denture retention (Figures 5 and 6). The mandibular anterior teeth exhibited good structural integrity and were therefore retained, except for tooth No. 23, which was removed and replaced by a single implant-supported crown (Implant Direct, 3.2 mm x 10 mm).

Six months after that, the LOCATOR attachment (Zest Dental Solutions) was assembled on the implants. The male part of the LOCATOR remained in contact with the attachment while the denture cap was fitted into the overdenture, as the LOCATOR implant attachment is designed to support the retention of implant-supported overdentures.

No technical or biological complications were observed pre- or post-prosthetic loading. The final prosthesis for the maxilla had a horseshoe design reinforced by a cast-metal framework.

DISCUSSION

Oral healthcare for patients who abuse drugs should include patient education and motivation, followed by prevention strategies as an integrated part of general healthcare services for addicts.⁶ Patients with a history of drug abuse, including a chemical dependency on opiates, require special attention in dental care and pain management.⁷

Before accepting the treatment plan and cooperating during treatment, patients must have confidence in their practitioners' abilities to manage their pain and anxieties during and after surgery.⁷ Most patients expect pain following oral surgery.⁸ The authors' treatment plan was for full-mouth extraction in the maxilla of the patient, who had avoided dental care for multiple reasons, including dental phobia. The authors' experience suggests that a combination of nonsteroidal and steroidal anti-inflammatory medications, along with prophylactic antibiotics, is more effective in controlling pain and anxiety when given as a pretreatment rather than post-oral surgery. This pretreatment establishes good rapport with the patient, who is then more inclined to accept treatment, followed by supportive maintenance therapy. The approach presented produced results that were well accepted by the patient and are supported by the literature.⁹

At the conclusion of his dental treatment, the patient's medical condition was well-controlled from an immunological and infectious disease standpoint. Special strategies are required for patients with oral and systemic conditions who need to smile with confidence. Optimal clinical decision-making is crucial to minimize the stress in these medically compromised patients.¹⁰ All factors of treatment complications or failure were present in this case, including poor oral hygiene, caries, periodontal disease, smoking, a compromised immune system, drug abuse, and hepatitis. However, the outcome would be very satisfactory with a proper oral health management program that includes education, prevention, and treatment planning for a patient with oral and systemic complications. Three years later, this patient is happy with the outcome of his oral health

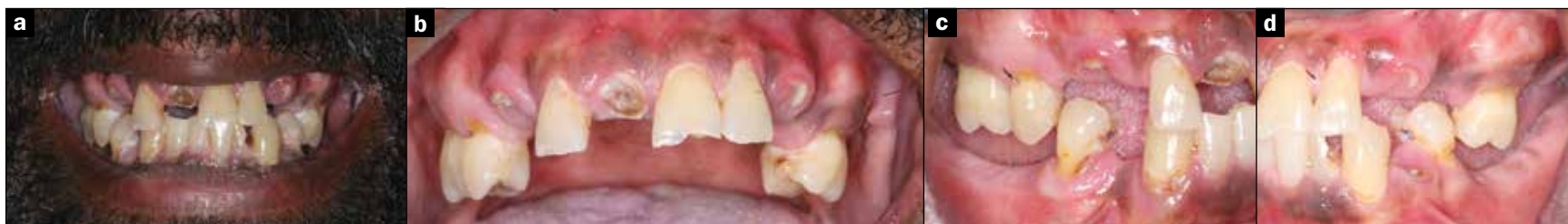

Figure 3. (a) The patient, smiling before treatment. (b) The maxillary teeth, frontal view. (c) The right lateral view. (d) The left lateral view.

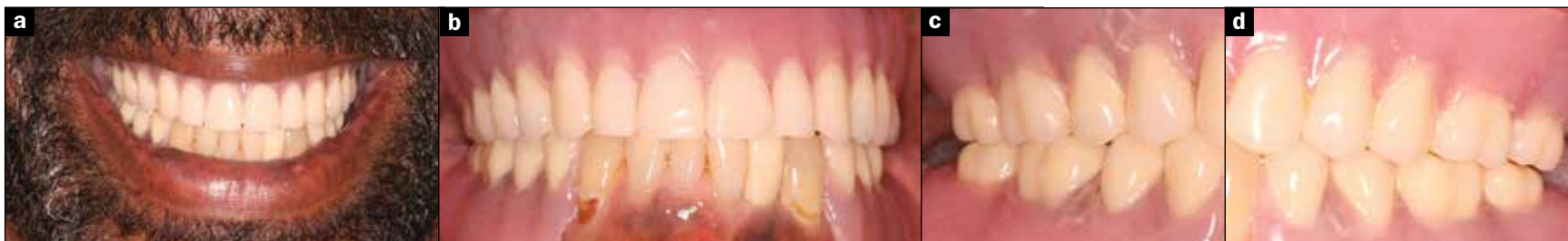

Figure 4. (a) The patient, smiling 3 years after successful treatment. (b) The frontal view (a non-carious cervical lesion was observed on the lower canines). (c) The right lateral view. (d) The left lateral view.

treatment. He smiles frequently and feels good about himself and the dentist who facilitated this positive outcome.

Since this patient was on antiretroviral medications, his CD4+ T-lymphocyte count was controlled. In addition, the approach of pre-medicating the patient with antibiotics and offering patient education and motivation helped achieve positive results. This is in accordance with the findings of Ata-Ali et al,¹¹ who reported that dental implant placement in HIV-positive patients does not increase the dental implant failure rate.

CONCLUSION

Maxillary overdentures and mandibular partial dentures supported by implants can be successful treatment modalities for patients who smoke and have compromised immune systems. The success of any prosthetic device depends on whether it is conducive to

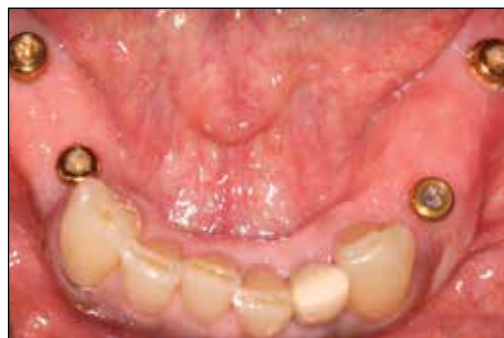

Figure 5. The mandibular occlusal view, showing locators in the posterior region, along with implant No. 23.

self-performed, effective oral hygiene with minimal effort. There are multiple advantages to using removable rather than fixed appliances to replace missing teeth, including ease of use.¹² The patient was 60 years old when he presented in 2015. Dexterity does not improve with age, and removable prostheses are easier for patients to maintain at home than fixed prostheses. Removable prostheses meet the challenge of aesthetic requirements by patients better than fixed prostheses because they replace hard and soft tissue, unlike fixed prostheses,

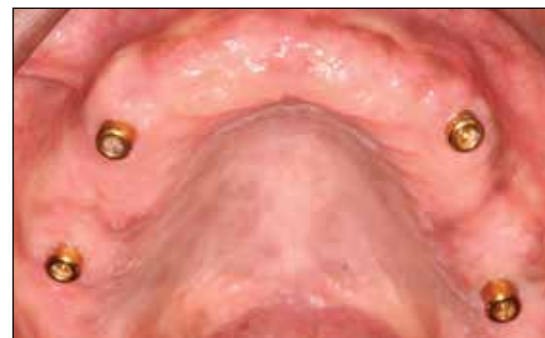

Figure 6. The maxillary occlusal view, showing implant positions along with a healthy and adequate width of alveolar ridge.

which mainly replace hard tissue. In addition, fixed prostheses are more frequently associated with halitosis than removable prostheses.¹² The patient stated that he wore his dentures 24 hours a day, 7 days a week, and removed them for hygiene only for a minute. The ease of maintenance and normal hygiene makes this system superior to fixed prostheses. This is also true for the dental office that maintains implants and prostheses.♦

References

- Centers for Disease Control and Prevention. HIV in the United States: At a glance. November 29,

2017. <https://www.cdc.gov/hiv/statistics/overview/ataglance.html>. Accessed May 17, 2018.

- Levy JA. Pathogenesis of human immunodeficiency virus infection. *Microbiol Rev.* 1993;57:183-289.
- Centers for Disease Control and Prevention. About HIV/AIDS. March 16, 2018. <https://www.cdc.gov/hiv/basics/whatishiv.html>. Accessed May 17, 2018.
- Weiss RA. How does HIV cause AIDS? *Science.* 1993;260:1273-1279.
- Baqui A, Meiller T, Jabra-Rizk M, et al. Association of HIV viral load with oral diseases. *Oral Dis.* 1999;5:294-298.
- Shekarchizadeh H, Khami MR, Mohebbi SZ, et al. Oral health of drug abusers: a review of health effects and care. *Iran J Public Health.* 2013;42:929-940.
- Sainsbury D. Drug addiction and dental care. *N Z Dent J.* 1999;95:58-61.
- Mei CC, Lee FY, Yeh HC. Assessment of pain perception following periodontal and implant surgeries. *J Clin Periodontol.* 2016;43:1151-1159.
- Peres MF, Ribeiro FV, Ruiz KG, et al. Steroidal and non-steroidal cyclooxygenase-2 inhibitor anti-inflammatory drugs as pre-emptive medication in patients undergoing periodontal surgery. *Braz Dent J.* 2012;23:621-628.
- Mersel A. Immediate or transitional complete dentures: gerodontic considerations. *Int Dent J.* 2002;52:298-303.
- Ata-Ali J, Ata-Ali F, Di Benedetto N, et al. Does HIV infection have an impact upon dental implant osseointegration? A systematic review. *Med Oral Patol Oral Cir Bucal.* 2015;20:e347-e356.
- Salierno C. Are implant overdentures on the rise? *Dent Econ.* 2017;107:16.

AUGUST: MORE OPPORTUNITIES TO EARN CE CREDIT

Replacing 2 Mandibular Incisors with One Implant: A Commentary

Gary Greenstein, DDS, MS; Joseph Carpentieri, DDS; and Ben Greenstein, DMD, present a commentary that addresses replacing 2 mandibular incisors with one implant to support 2 crowns. Two techniques are compared: cantilevered pontic vs 2 crowns geminating off the implant.

This article is peer reviewed and available for 2 hours of CE credit.



To submit Continuing Education (CE) answers, use the answer sheet below. Or, use our easy online option at dentalcetoday.com. This article is available for 2 hours of CE credit. The following 10 questions were derived from "Treatment Planning in Immunocompromised Patients: Case Report" by Ahmad Soolari, DMD, MS, and Amin Soolari, BS, CDRT, on pages 120 to 122.

Learning Objectives: After reading this article, the individual will learn: (1) treatment planning considerations for patients with numerous oral and systemic health problems, and (2) treatment protocol for a patient with multiple oral and systemic health problems. **Subject Code:** 750.

1. **How many people in the United States are living with human immunodeficiency virus (HIV)?**
 - a. 500,000.
 - b. 1.1 million.
 - c. 2.1 million.
 - d. 3 million.
2. **The HIV virus is transmitted through blood and genital fluids. The virus specifically targets CD4 cells of the immune system.**
 - a. The first statement is true; the second is false.
 - b. The first statement is false; the second is true.
 - c. Both statements are true.
 - d. Both statements are false.
3. **The normal range for CD4 cells is:**
 - a. 100 to 500.
 - b. 500 to 1,500.
 - c. 1,500 to 2,000.
 - d. 2,000 to 3,000.
4. **In HIV patients, the viral load measurement is a good predictor of disease progression, especially in drug abusers.**
 - a. True.
5. **In the case presented, bone grafting was performed with freeze-dried bone allograft. A non-resorbable, titanium-reinforced cytoplast membrane was customized to promote bone regeneration.**
 - a. The first statement is true; the second is false.
 - b. The first statement is false; the second is true.
 - c. Both statements are true.
 - d. Both statements are false.
6. **In the case presented, how long after implant placement were the implant attachments assembled on the implants?**
 - a. 3 months.
 - b. 6 months.
 - c. 8 months.
 - d. 10 months.
7. **In the case presented, the patient had the following condition(s):**
 - a. HIV.
 - b. Hepatitis B and C.
 - c. Chronic kidney disease.
 - d. All of the above.
8. **In the case presented, the patient was taking antiretroviral medications to control his CD4+ T-lymphocyte count. According to the literature, dental implant placement in HIV-positive patients does not increase implant failure rate.**
 - a. The first statement is true; the second is false.
 - b. The first statement is false; the second is true.
 - c. Both statements are true.
 - d. Both statements are false.
9. **In the context of the case presented, removable prostheses are easier for patients to maintain at home than fixed prostheses.**
 - a. True.
 - b. False.
10. **In the case presented, the patient was pre-medicated orally with:**
 - a. Amoxicillin.
 - b. Ibuprofen.
 - c. Methylprednisolone.
 - d. All of the above.

ANSWER SHEET Test 223, beginning on page 120

Complete the paper answer sheet and submit your answers for this issue's CE examination. Answer at least 7 of the 10 questions correctly to earn 2 CE credits.

Please check the correct box for each question below.

1. a b c d
2. a b c d
3. a b c d
4. True False
5. a b c d
6. a b c d
7. a b c d
8. a b c d
9. True False
10. a b c d

Mail or fax this completed form with payment to:

**Dentistry Today Department of Continuing Education,
100 Passaic Avenue, Fairfield, NJ 07004
Fax: (973) 882-3622**

PAYMENT & CREDIT INFORMATION:

Examination Fee: \$40.00 Credit Hours: 2.0
Note: There is a \$10 surcharge to process a check drawn on any bank other than a US bank. Should you have additional questions, please contact us at (973) 882-4700.

- I have enclosed a check or money order.
 I am using a credit card.
 My credit card information is provided below.
 American Express Visa MC Discover
 Please provide the following (please print clearly):

Exact Name on Credit Card _____

Credit Card # _____ Expiration Date _____

Signature _____

**Complete online at: dentalcetoday.com
Immediate results with a printable letter upon completion.**

PERSONAL CERTIFICATION INFORMATION:

Last Name (PLEASE PRINT CLEARLY OR TYPE)

First Name

Profession / Credentials License Number AGD ID Number

Street Address

Suite or Apartment Number

City State Zip Code

Daytime Telephone Number With Area Code

Fax Number With Area Code

Email Address

PROGRAM EVALUATION FORM

Please complete the following activity evaluation questions.
 Rating Scale: Excellent = 5 and Poor = 0
 Course objectives were achieved.
 Content was useful and benefited your clinical practice.
 Review questions were clear and relevant to the editorial.
 Illustrations and photographs were clear and relevant.
 Written presentation was informative and concise.
 How much time did you spend reading the activity and completing the test?
 What aspect of this course was most helpful and why?

What topics interest you for future *Dentistry Today* CE courses?



Dentistry Today, Inc.
Nationally Approved PACE Program Provider for FAGD/MAGD credit. Approval does not imply acceptance by any regulatory authority or AGD endorsement.
June 1, 2018 to May 31, 2022.
Provider ID# 309062

MAIL IN ANSWER SHEET TODAY



Dentistry Today, Inc. is an ADA CER-P Recognized Provider. ADA CER-P is a service of the American Dental Association to assist dental professionals in identifying quality providers of continuing dental education. ADA CER-P does not approve or endorse individual courses or instructors, nor does it imply acceptance of credit hours by boards of dentistry. Concerns or complaints about a CE provider may be directed to the provider or to ADA CER-P at ada.org/goto/cerp.

Opinions expressed by CE authors are their own and may not reflect those of *Dentistry Today*. Mention of specific product names does not infer endorsement by *Dentistry Today*. Information contained in CE articles and courses is not a substitute for sound clinical judgment and accepted standards of care. Participants are urged to contact their state dental boards for continuing education requirements.