



# Management of Mandibular Anterior Teeth With Gingival Recession

*Ahmad Soolari, DMD, MS; Amin Soolari, CRDT; and Randa Alobaidi, CRDT*

**Upon successful completion of this CE activity, 2 CE credit hours may be awarded**

A Peer-Reviewed CE Activity by



**ADA CERP**® | Continuing Education Recognition Program

Dentistry Today, Inc. is an ADA CERP Recognized Provider. ADA CERP is a service of the American Dental Association to assist dental professionals in identifying quality providers of continuing dental education. ADA CERP does not approve or endorse individual courses or instructors, nor does it imply acceptance of credit hours by boards of dentistry. Concerns or complaints about a CE provider may be directed to the provider or to ADA CERP at [ada.org/goto/cerp](http://ada.org/goto/cerp).



Approved PACE Program Provider FAGD/MAGD Credit Approval does not imply acceptance by a state or provincial board of dentistry or AGD endorsement. June 1, 2012 to May 31, 2015 AGD PACE approval number: 309062

Opinions expressed by CE authors are their own and may not reflect those of *Dentistry Today*. Mention of specific product names does not infer endorsement by *Dentistry Today*. Information contained in CE articles and courses is not a substitute for sound clinical judgment and accepted standards of care. Participants are urged to contact their state dental boards for continuing education requirements.

# Management of Mandibular Anterior Teeth With Gingival Recession

Effective Date: 02/01/2015 Expiration Date: 02/01/2018

**Learning Objectives:** After reading this article, the individual will learn: (1) clinical options for managing localized gingival recession, and (2) a technique for restoring root coverage, reducing sensitivity, and achieving aesthetics in a case of Miller Class II gingival recession.

## About the Authors



**Dr. Ahmad Soolari** is a Diplomate of the American Board of Periodontology. He has a certificate in periodontics from the Eastman Institute and an MS degree from the University of Rochester, Rochester, NY. Dr. Soolari operates a specialty practice in the Silver Spring, Gaithersburg, and Potomac areas of Montgomery County, Md. He can be reached at [asoolari@gmail.com](mailto:asoolari@gmail.com).



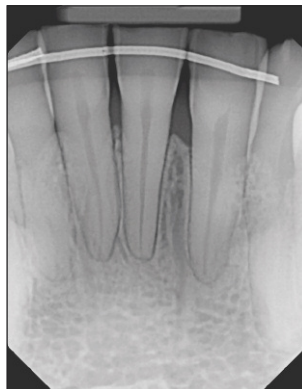
**Mr. Amin Soolari** is a student in the pre-dental program at the University of Maryland. He has been a dental assistant for 6 years and has experience in orthodontics, periodontics, and assisting in general treatment and oral surgery. He is currently taking courses to prepare for dental school. He started his career in a periodontal office, where he became a certified dental radiation technologist (CDRT). He can be reached at [amin.soolari@gmail.com](mailto:amin.soolari@gmail.com).



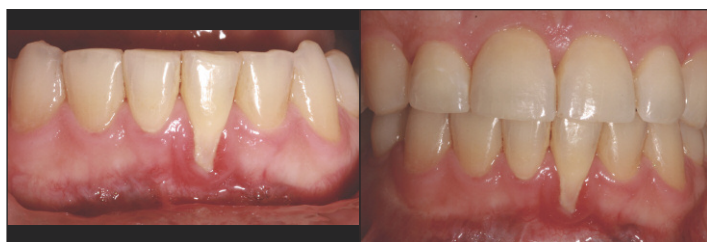**Mrs. Alobaidi** is a CDRT and a student in the pre-dental hygiene program at the Northern Virginia Community College. She has been a dental assistant for 3 years and has experience in periodontics and implantology. She started her career in a periodontal office, where she became CDRT. She can be reached by email at [randaalobaidi@gmail.com](mailto:randaalobaidi@gmail.com).

*Disclosures: The authors report no disclosures.*

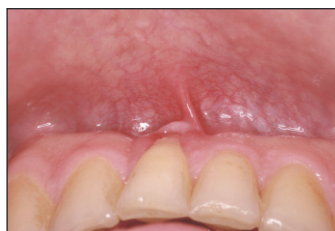**G**ingival recession is common, with reported prevalences ranging between 17% and 87.5% in populations of all ages.<sup>1-6</sup> Recession that extends beyond the mucogingival junction may be caused by any number of factors, including a history of orthodontic treatment, occlusal trauma,



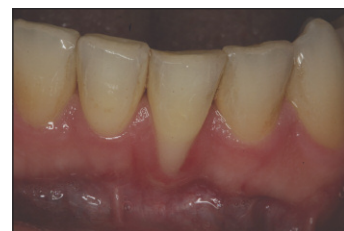**Figure 1.** Pretreatment radiograph. Note the interproximal bone loss between the mandibular anterior teeth. The patient's chief complaints were sensitivity and concerns with losing the left central incisor (tooth No. 24).



**Figures 2 and 3.** Pretreatment views emphasizing the severe gingival recession beyond the mucogingival junction on tooth No. 24. Note the impact of gingival recession on tooth No. 24: a highly inflamed gingiva and heavy plaque buildup that is not present on adjacent teeth.



**Figure 4.** Occlusal view of aberrant frenum and mucogingival deformity beyond the mucogingival junction along with plaque buildup on tooth No. 24.



**Figure 5.** The impact of scaling and root planing on tooth No. 24; improvements in tissue color, contour, and consistency are apparent.

misaligned teeth or teeth that are positioned outside of the alveolar housing, periodontitis, improper brushing, inadequate attached gingiva, frenal pull, and a shallow vestibule.<sup>6-9</sup> Recession may also be associated with deep gingival pockets, bleeding on probing, heavy plaque buildup, tooth sensitivity, root caries, and a poor crown-to-root ratio. Patients are often concerned about the progressive nature of gingival recession, as well as aesthetic problems.

The anterior mandible is a challenging area for clinicians when gingival recession occurs.<sup>10</sup> The frenal pull, shallow vestibule, and narrow interdental space render correction difficult. However, numerous studies have shown that gingival re-

## Management of Mandibular Anterior Teeth With Gingival Recession

cession in this area can be successfully treated with tissue grafting.<sup>10,11</sup> Root coverage can be restored, the volume of keratinized tissue can be augmented, sensitivity can be lessened, and aesthetic problems can be mitigated with grafting.

In the case presented, a combination of subepithelial connective tissue graft (SECTG) along with a coronally advanced flap was able to achieve 100% root coverage of a Miller Class II gingival recession.<sup>11</sup>

### CASE REPORT

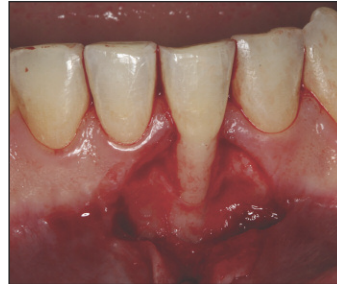A 34-year-old man was referred for treatment of gingival recession. He presented with a problematic mandibular left central incisor (tooth No. 24), which displayed progressive gingival recession (Figures 1 to 3). He had undergone orthodontic treatment twice, first at age 15 and again a few years prior to presenting in our office.

The initial clinical examination disclosed gingival recession beyond the mucogingival junction (Miller Class II), an aberrant frenum (Figure 4), a lack of attached gingiva, deep pocket, bleeding on probing, and occlusal trauma. All of these factors plus the 2 courses of orthodontic treatment may have contributed to the recession. The patient also reported sensitivity in the area.

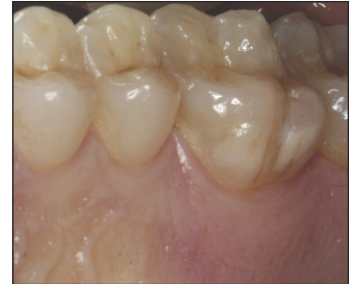The proposed treatment plan called for tissue grafting after scaling and root planing, occlusal adjustment, frenectomy, and delivery of an occlusal guard. Following application of local anesthesia, contaminated cementum was removed from the root of tooth No. 24 by a combination of hand and ultrasonic instruments (Figure 5).

Treatment of this tooth was similar to another recent case, a molar implant with gingival deformity on the facial aspect.<sup>12</sup> To prevent further attachment loss and to restore the damaged area, a SECTG was harvested as described by Langer and Langer<sup>13</sup> to reconfigure the soft tissue into ideal contours and ensure optimal periodontal health. The initial sulcular incision was made with a No. 15c blade (Carbon Steel [Benco Dental]), followed by vertical incisions to prepare the recipient site to accommodate the SECTG. The facial full-thickness flap extended apically beyond the mucogingival junction, and then became a split-thickness flap at its most apical part so that it could be relaxed completely for coronal advancement. Flap reflection enabled observation of significant bone loss on the facial aspect of tooth No. 24 (Figure 6). This serves as a reminder that gingival recession is a sign of bone loss that needs treatment.

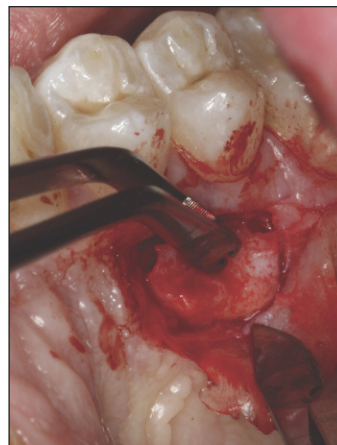Bone grafting was not performed. In the authors' view, this mucogingival deformity was not associated with an infectious process in this patient. Another reason to refrain from bone grafting at the same time as soft-tissue grafting is that the newly placed connective tissue on the facial aspect of tooth No. 24 would require a blood supply from underneath the vital struc-



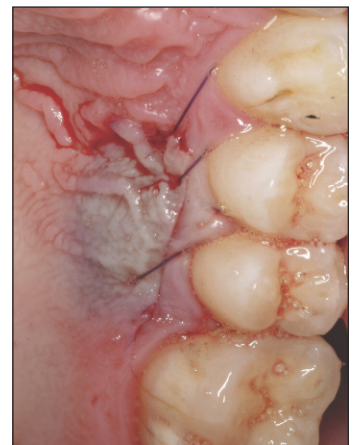
**Figure 6.** Periodontal surgery was performed to gain access to tooth root and bony defect. Severe loss of the supporting structure on the facial aspect of tooth No. 24 is apparent.



**Figure 7.** Graft site on the palatal aspect of premolars to harvest a connective tissue graft.



**Figure 8.** A thick connective tissue graft was harvested from the premolar region.

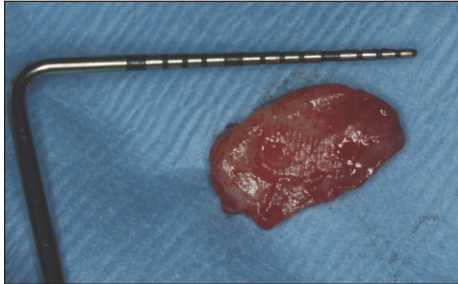


**Figure 9.** The donor site was closed.

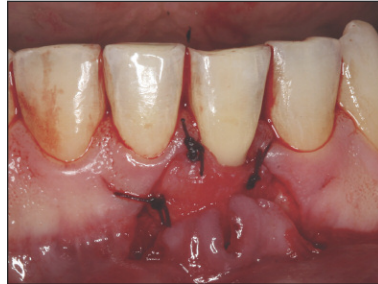tures to survive, and the nonvital implanted bone graft could not assist in the survival of another entity (connective tissue). However, bone grafting can be done after soft-tissue grafting when the deficiency of soft tissue at the recipient site has been corrected. Because the lack of soft tissue at the recipient site was pronounced, a large graft was harvested (Figures 7 to 10) from the premolar area, since it has the potential to provide thicker grafts with adequate vascularity that are less likely to recede.<sup>14,15</sup> A thick portion (15 x 10 x 4 mm) of connective tissue was obtained from the maxillary left palate in the canine/premolar region (Figures 8 to 10), adapted to the recipient site, and secured with single interrupted 5.0 Vicryl sutures (polyglactin 910, P3 [Ethicon]) (Figure 11). Next, the flap was positioned coronally to provide complete coverage of the graft (Figure 12).

To prevent post-treatment infection, pain, and swelling, the patient was given amoxicillin orally (500 mg tid), ibuprofen

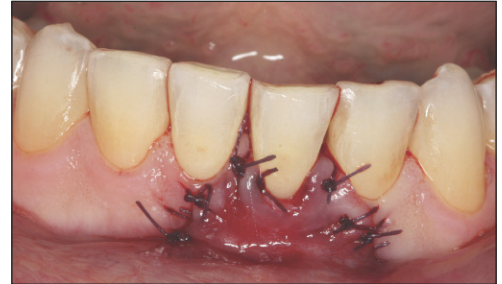## Management of Mandibular Anterior Teeth With Gingival Recession



**Figure 10.** A thick (10 x 5 x 2 mm) graft of connective tissue was harvested from the maxillary left palate in the canine/premolar region.



**Figure 11.** The graft was adapted and secured to the recipient site with single interrupted 5.0 Vicryl sutures (Ethicon).



**Figure 12.** The flap then released internally and coronally advanced to completely cover the connective tissue graft. It was secured with single interrupted 5.0 Vicryl sutures.

(800 mg, tid as needed), and methylprednisolone (Medrol Dosepack). Additionally, a chlorhexidine rinse (chlorhexidine gluconate [Acclean], 0.12% oral rinse USP) was used twice daily.

The results are shown at 18 months in Figures 13 and 14. In this case, the patient was pleased because his concerns were resolved. The aesthetic concern of the tooth appearing longer than its neighbors was gone, there was little to no plaque buildup on the treated tooth compared to the adjacent teeth, the sensitivity had been eliminated, the exposed root was completely covered, and the inflamed and bleeding gums were resolved. At 18 months post-treatment, there was an increase of 6 mm in tissue height, lack of frenum pull, deepening of the vestibule, realignment of the mucogingival junction, and a strengthened supporting structure of the mandibular anterior teeth.

### DISCUSSION

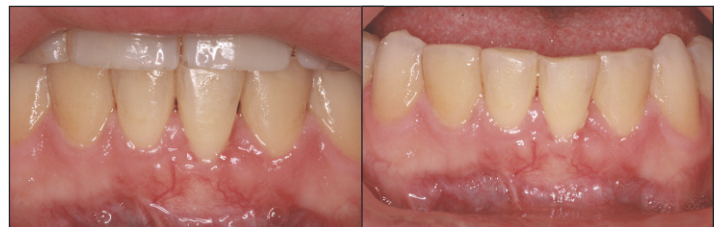#### Management of Localized Severe Gingival Recession

Gingival recession is common, even in the most conscientious patients; Matas et al<sup>5</sup> observed it in 85% of dental students. Therefore, all possible approaches to its management must be considered for patients. Options would include observation without treatment, placement of restorative material, removal of the tooth and replacement with an implant, or gingival augmentation.

The first option, observation, is free of charge, but further breakdown of the supporting structure of the affected tooth is almost inevitable. Restorative options include the placement of white or pink restorative material, such as composite, to improve aesthetics in the area. However, this would not be very stable and would not correct the “roller coaster” tissue profile that hints at the underlying loss of hard and soft tissue (and the weakening support for the tooth). Goldstein et al<sup>16</sup> noted that this approach may even complicate the problem rather than resolving it, and the authors of this article have noted the same in our practice. Restorative materials may mask underlying pathology, which

can be difficult to diagnose radiographically and fully discerned only through a surgical approach, and allow additional plaque and calculus to accumulate in the area. Also, throughout time, an aesthetic mismatch may develop between the restoration and the patient’s natural dentition, necessitating further treatment and perhaps removal of additional vital tooth structure to remedy the problem.

It has become increasingly common to remove a tooth that has caries, mild to moderate periodontal disease, or infected pulp, and replace it with an implant. Although implant technologies and techniques have made great strides in recent decades, replacement of a vital tooth with an implant can be problematic for many reasons. First, the tissues around implants are more susceptible to plaque-associated infections, and areas of infection have been reported to be larger and extend more apically when compared to natural dentition.<sup>17</sup> In patients susceptible to periodontitis, as the present patient was, the risk of peri-implantitis is higher. In addition, treatment of peri-implantitis is not predictable.<sup>18</sup> Implants are more expensive to maintain than teeth,<sup>19</sup> and biological and technical complications are common. Lang et al,<sup>20</sup> in a consensus



**Figures 13 and 14.** Clinical appearance at 18 months after treatment. Root coverage was achieved and the patient’s chief complaints were addressed successfully. The resolution of the gingival deformity brought peace to the patient, who had discomfort and was concerned with losing the tooth. The harmony of the soft tissue supporting tooth No. 24 with neighboring teeth is apparent, and this could not have been achieved with removal of the tooth and replacement with a dental implant.

## Management of Mandibular Anterior Teeth With Gingival Recession

statement and recommendations regarding implant treatment, noted that complications occurred in about 50% of patients treated with implant-supported prostheses after 10 years in function. In the long term, implants do not surpass the longevity of even compromised but successfully treated natural teeth, as found by Holm-Pedersen et al.<sup>21</sup> In their review, the authors<sup>21</sup> found survival rates, even for periodontally compromised teeth, of up to 93% after 50-plus years, whereas reported oral implant survival rates after 10-plus years are between 82% and 94%. Further, in the mandible, the inferior alveolar nerve usually ends prior to the anterior area, making most implant placement safe, but occasionally the canal is extended,<sup>22</sup> resulting in nerve damage. Also, although narrow implants are available, they may be problematic due to the limited interdental space in the anterior mandible.

The fourth option for the treatment of gingival recession, gingival augmentation, has been shown through numerous studies throughout many years to be a predictable procedure. The greater the thickness of the flap, the better the root coverage.<sup>23</sup> A variety of materials and approaches have been used to restore the gingiva, although free gingival grafts may have the disadvantage of sometimes regenerating the rugae of the donor site.<sup>24</sup> Agudio et al<sup>25</sup> found that free gingival grafting is especially successful in the anterior region; they observed significantly better results for canines/incisors than molars/premolars in terms of keratinized tissue gain. Bethaz et al<sup>10</sup> also observed that mandibular anterior grafting of multiple sites in 7 patients preserved vestibular depth and was predictable. After 2 years, 73.3% of root surfaces were still completely covered. Kuru and Yildirim<sup>26</sup> treated mandibular anterior teeth with “gingival-unit grafts” in efforts to ensure a healthy vascular supply and guarantee excellent restoration of gingiva. They<sup>26</sup> noted that “conventional free palatal grafts, modified with the involvement of marginal gingiva and papillary tissue (described as the gingival unit), may have an uncommon capacity for perfusion and survival on the exposed root surfaces” and they successfully treated Miller Class I and II defects with this approach. Coverage, attachment, and keratinized tissue were all improved versus conventional grafts. Nart et al<sup>11</sup> achieved complete coverage of mandibular incisors with subepithelial connective tissue grafts and a coronally advanced flap. Mahajan et al<sup>27</sup> achieved superior results with acellular dermal matrix graft plus a coronally positioned flap, versus a flap alone, to treat Miller Class I and II defects. Zucchelli and De Sanctis<sup>28</sup> achieved coverage of Miller Class II and III defects with a 2-stage procedure. Complete root coverage, increased keratinized tissue thickness, and aesthetic harmony were achieved. Even carious teeth can be treated predictably: Goldstein et al<sup>16</sup> achieved equivalent success after grafting 33 intact teeth and 27 teeth with carious roots.

A further advantage of gingival grafting over other approaches is its ability to regenerate the supporting tissues. Agudio et al<sup>25</sup> found that creeping attachment (ie, coronal migration of the gingival margin, with continuing good probing depths) continued, even at 10 to 25 years after free gingival grafting. Goldstein et al<sup>29</sup> found that, after subepithelial connective tissue grafting, all the attachment apparatus of teeth was regenerated, including bone, cementum, and periodontal ligament. An implant, in contrast, cannot contribute living tissue to regenerate any supporting apparatus, and it can be difficult to create gingival harmony with neighboring teeth, as interdental bone in particular will still be lacking.

In the current case, the treatment regenerated the gingiva that had been injured, damaged, or lost. The most ideal treatment plan was to augment the gingiva on the mandibular left central incisor with gingival grafts. This was done to facilitate home care, resist trauma and abrasion from brushing, prevent root caries, and resolve the sensitivity. The treatment was also aesthetically pleasing, because the exposed root problem was resolved and the tissue profile was placed back in line with the adjacent teeth.

This case report illustrates why the referral team approach is beneficial for both patients and referring doctors. The patient is very happy with the outcome and is also pleased with the referring doctor.

### CONCLUSION

Gingival grafting can help to strengthen the gums and reduce gingival inflammation, reduce the risk of root caries due to better plaque control, reduce or eliminate root sensitivity in covered areas, and improve gingival aesthetics by covering exposed roots with healthy tissue. The result will be healthy and happy patients who feel good about their teeth and their dentists (Figures 13 and 14).

Sometimes a tooth that is diagnosed as hopeless is not so hopeless. If recession is managed properly, the tooth can be brought back to normal function and the supporting tissue can be regenerated. Perfection may not be possible, but more conservative and less expensive treatment may appeal to patients. Even if 100% root coverage is not accomplished, much can be achieved, including resolution of root sensitivity.

The authors advocate a balanced approach between implants and periodontal regenerative therapy (eg, grafting). We advise exploring the options on a case-by-case basis with patients and cross-disciplinary colleagues, and working together as a team to accomplish cost-effective, positive outcomes.

### Acknowledgment

The authors thank Jennifer P. Ballinger, ELS, for assistance in drafting this manuscript.

# Management of Mandibular Anterior Teeth With Gingival Recession

## References

1. Mathur A, Jain M, Jain K, et al. Gingival recession in school kids aged 10-15 years in Udaipur, India. *J Indian Soc Periodontol*. 2009;13:16-20.
2. Chrysanthakopoulos NA. Gingival recession: prevalence and risk indicators among young Greek adults. *J Clin Exp Dent*. 2014;6:e243-e249.
3. Nguyen-Hieu T, Ha Thi BD, Do Thu H, et al. Gingival recession associated with predisposing factors in young Vietnamese: a pilot study. *Oral Health Dent Manag*. 2012;11:134-144.
4. Minaya-Sánchez M, Medina-Solís CE, Vallejos-Sánchez AA, et al. Gingival recession and associated factors in a homogeneous Mexican adult male population: a cross-sectional study. *Med Oral Patol Oral Cir Bucal*. 2012;17:e807-e813.
5. Matas F, Sentís J, Mendieta C. Ten-year longitudinal study of gingival recession in dentists. *J Clin Periodontol*. 2011;38:1091-1098.
6. Stoner JE, Mazdyasna S. Gingival recession in the lower incisor region of 15-year-old subjects. *J Periodontol*. 1980;51:74-76.
7. Steiner GG, Pearson JK, Ainamo J. Changes of the marginal periodontium as a result of labial tooth movement in monkeys. *J Periodontol*. 1981;52:314-320.
8. Renkema AM, Fudalej PS, Renkema A, et al. Development of labial gingival recessions in orthodontically treated patients. *Am J Orthod Dentofacial Orthop*. 2013;143:206-212.
9. Tanaka OM, Avila AL, Silva GM, et al. The effects of orthodontic movement on a subepithelial connective tissue graft in the treatment of gingival recession. *J Contemp Dent Pract*. 2010;11:E073-E079.
10. Bethaz N, Romano F, Ferrarotti F, et al. A mucogingival technique for the treatment of multiple recession defects in the mandibular anterior region: a case series with a 2-year follow-up. *Int J Periodontics Restorative Dent*. 2014;34:345-352.
11. Nart J, Valles C, Mareque S, et al. Subepithelial connective tissue graft in combination with a coronally advanced flap for the treatment of Miller Class II and III gingival recessions in mandibular incisors: a case series. *Int J Periodontics Restorative Dent*. 2012;32:647-654.
12. Soolari A, Soolari N. Management of plaque-related soft tissue trauma. *Dent Today*. 2013;32:96-99.
13. Langer B, Langer L. Subepithelial connective tissue graft technique for root coverage. *J Periodontol*. 1985;56:715-720.
14. Reiser GM, Bruno JF, Mahan PE, et al. The subepithelial connective tissue graft palatal donor site: anatomic considerations for surgeons. *Int J Periodontics Restorative Dent*. 1996;16:130-137.
15. Lorenzana ER, Allen EP. The single-incision palatal harvest technique: a strategy for esthetics and patient comfort. *Int J Periodontics Restorative Dent*. 2000;20:297-305.
16. Goldstein M, Nasatzky E, Goultschin J, et al. Coverage of previously carious roots is as predictable a procedure as coverage of intact roots. *J Periodontol*. 2002;73:1419-1426.
17. Lindhe J, Berglundh T, Ericsson I, et al. Experimental breakdown of peri-implant and periodontal tissues. A study in the beagle dog. *Clin Oral Implants Res*. 1992;3:9-16.
18. Lindhe J, Meyle J; Group D of European Workshop on Periodontology. Peri-implant diseases: Consensus Report of the Sixth European Workshop on Periodontology. *J Clin Periodontol*. 2008;35(suppl 8):282-285.
19. Fardal Ø, Grytten J. A comparison of teeth and implants during maintenance therapy in terms of the number of disease-free years and costs—an in vivo internal control study. *J Clin Periodontol*. 2013;40:645-651.
20. Lang NP, Berglundh T, Heitz-Mayfield LJ, et al. Consensus statements and recommended clinical procedures regarding implant survival and complications. *Int J Oral Maxillofac Implants*. 2004;19(suppl):150-154.
21. Holm-Pedersen P, Lang NP, Müller F. What are the longevities of teeth and oral implants? *Clin Oral Implants Res*. 2007;18(suppl 3):15-19.
22. Kütük N, Demirba AE, Gönen ZB, et al. Anterior mandibular zone safe for implants. *J Craniofac Surg*. 2013;24:e405-e408.
23. Hwang D, Wang HL. Flap thickness as a predictor of root coverage: a systematic review. *J Periodontol*. 2006;77:1625-1634.
24. Breault LG, Fowler EB, Billman MA. Retained free gingival graft rugae: a 9-year case report. *J Periodontol*. 1999;70:438-440.
25. Agudio G, Nieri M, Rotundo R, et al. Free gingival grafts to increase keratinized tissue: a retrospective long-term evaluation (10 to 25 years) of outcomes. *J Periodontol*. 2008;79:587-594.
26. Kuru B, Yildirim S. Treatment of localized gingival recessions using gingival unit grafts: a randomized controlled clinical trial. *J Periodontol*. 2013;84:41-50.
27. Mahajan A, Dixit J, Verma UP. A patient-centered clinical evaluation of acellular dermal matrix graft in the treatment of gingival recession defects. *J Periodontol*. 2007;78:2348-2355.
28. Zucchelli G, De Sanctis M. Modified two-stage procedures for the treatment of gingival recession. *Eur J Esthet Dent*. 2013;8:24-42.
29. Goldstein M, Boyan BD, Cochran DL, et al. Human histology of new attachment after root coverage using subepithelial connective tissue graft. *J Clin Periodontol*. 2001;28:657-662.

# Management of Mandibular Anterior Teeth With Gingival Recession

## POST EXAMINATION INFORMATION

To receive continuing education credit for participation in this educational activity, you must complete the program post examination and receive a score of 70% or better.

### Traditional Completion Option:

You may fax or mail your answers with payment to *Dentistry Today* (see Traditional Completion Information on following page). All information requested must be provided in order to process the program for credit. Be sure to complete your "Payment," "Personal Certification Information," "Answers," and "Evaluation" forms. Your exam will be graded within 72 hours of receipt. Upon successful completion of the post-exam (70% or higher), a letter of completion will be mailed to the address provided.

### Online Completion Option:

Use this page to review the questions and mark your answers. Return to **dentalcetoday.com** and sign in. If you have not previously purchased the program, select it from the "Online Courses" listing and complete the online purchase process. Once purchased, the program will be added to your **User History** page where a **Take Exam** link will be provided directly across from the program title. Select the **Take Exam** link, complete all the program questions and **Submit** your answers. An immediate grade report will be provided. Upon receiving a passing grade, complete the online evaluation form. Upon submitting the form, your **Letter of Completion** will be provided immediately for printing.

### General Program Information:

Online users may log in to **dentalcetoday.com** any time in the future to access previously purchased programs and view or print letters of completion and results.

## POST EXAMINATION QUESTIONS

### 1. Gingival recession that extends beyond the mucogingival junction may be caused by:

- Orthodontic treatment.
- Occlusal trauma.
- Improper tooth brushing.
- All of the above.

### 2. Treating gingival recession in the anterior mandible is particularly difficult due to:

- Frenal pull.
- Shallow vestibule.
- Narrow interdental space.
- All of the above.

### 3. Tissues around implants are more susceptible to plaque-associated infection compared to natural teeth. Areas of infection around implants have been reported to be larger and extend more apically compared to natural teeth.

- The first statement is true, the second is false.
- The first statement is false, the second is true.
- Both statements are true.
- Both statements are false.

### 4. Lang et al found that complications occurred in approximately \_\_\_ of patients treated with implant-supported prostheses after 10 years in function.

- 30%.
- 40%.
- 50%.
- 60%.

### 5. Agudio et al found that free gingival grafting achieved significantly better results for canines/incisors than for molars/premolars in terms of keratinized tissue gain.

- True.
- False.

### 6. Gingival augmentation has been shown to be predictable in treating gingival recession. The thinner the flap, the better the root coverage.

- The first statement is true, the second is false.
- The first statement is false, the second is true.
- Both statements are true.
- Both statements are false.

### 7. A 2-stage procedure involving tissue grafting plus a coronally positioned flap should not be used on teeth with carious roots.

- True.
- False.

## Management of Mandibular Anterior Teeth With Gingival Recession

**8. One advantage of free gingival grafting is its ability to regenerate supporting tissues. Creeping attachment may continue 10 to 25 years after free gingival grafting.**

- a. The first statement is true, the second is false.
- b. The first statement is false, the second is true.
- c. Both statements are true.
- d. Both statements are false.

**9. Goldstein et al found that after subepithelial connective tissue grafting, the following was/were regenerated:**

- a. Bone.
- b. Cementum.
- c. Periodontal ligament.
- d. All of the above.

**10. Gingival grafting can accomplish the following:**

- a. Reduce gingival inflammation.
- b. Reduce the risk of root caries.
- c. Reduce or eliminate root sensitivity.
- d. All of the above.





# Management of Mandibular Anterior Teeth With Gingival Recession

## PROGRAM COMPLETION INFORMATION

If you wish to purchase and complete this activity traditionally (mail or fax) rather than online, you must provide the information requested below. Please be sure to select your answers carefully and complete the evaluation information. To receive credit you must answer at least 8 of the 10 questions correctly.

Complete online at: [dentalcetoday.com](http://dentalcetoday.com)

## TRADITIONAL COMPLETION INFORMATION:

Mail or fax this completed form with payment to:

**Dentistry Today**  
**Department of Continuing Education**  
**100 Passaic Avenue**  
**Fairfield, NJ 07004**  
**Fax: 973-882-3622**

## PAYMENT & CREDIT INFORMATION:

Examination Fee: \$40.00 Credit Hours: 2.0

Note: There is a \$10 surcharge to process a check drawn on any bank other than a US bank. Should you have additional questions, please contact us at (973) 882-4700.

- I have enclosed a check or money order.
- I am using a credit card.

My Credit Card information is provided below.

- American Express  Visa  MC  Discover

Please provide the following (please print clearly):

Exact Name on Credit Card \_\_\_\_\_

Credit Card # \_\_\_\_\_ / \_\_\_\_\_  
Expiration Date

Signature \_\_\_\_\_



Approved PACE Program Provider  
FAGD/MAGD Credit Approval does not imply acceptance by a state or provincial board of dentistry or AGD endorsement. June 1, 2012 to May 31, 2015 AGD PACE approval number: 309062



Continuing Education Recognition Program  
Dentistry Today, Inc. is an ADA CERP Recognized Provider. ADA CERP is a service of the American Dental Association to assist dental professionals in identifying quality providers of continuing dental education. ADA CERP does not approve or endorse individual courses or instructors, nor does it imply acceptance of credit hours by boards of dentistry. Concerns or complaints about a CE provider may be directed to the provider or to ADA CERP at [ada.org/goto/cerp](http://ada.org/goto/cerp).

## PERSONAL CERTIFICATION INFORMATION:

Last Name (PLEASE PRINT CLEARLY OR TYPE) \_\_\_\_\_

First Name \_\_\_\_\_

Profession / Credentials \_\_\_\_\_ License Number \_\_\_\_\_

Street Address \_\_\_\_\_

Suite or Apartment Number \_\_\_\_\_

City \_\_\_\_\_ State \_\_\_\_\_ Zip Code \_\_\_\_\_

Daytime Telephone Number With Area Code \_\_\_\_\_

Fax Number With Area Code \_\_\_\_\_

E-mail Address \_\_\_\_\_

## ANSWER FORM: COURSE #: 182

Please check the correct box for each question below.

- 1.  a  b  c  d
- 2.  a  b  c  d
- 3.  a  b  c  d
- 4.  a  b  c  d
- 5. True False
- 6.  a  b  c  d
- 7. True False
- 8.  a  b  c  d
- 9.  a  b  c  d
- 10.  a  b  c  d

## PROGRAM EVALUATION FORM

Please complete the following activity evaluation questions.

Rating Scale: Excellent = 5 and Poor = 0

Course objectives were achieved. \_\_\_\_\_

Content was useful and benefited your clinical practice. \_\_\_\_\_

Review questions were clear and relevant to the editorial. \_\_\_\_\_

Illustrations and photographs were clear and relevant. \_\_\_\_\_

Written presentation was informative and concise. \_\_\_\_\_

How much time did you spend reading the activity and completing the test? \_\_\_\_\_

What aspect of this course was most helpful and why? \_\_\_\_\_

What topics interest you for future Dentistry Today CE courses? \_\_\_\_\_